

The Curious Case of Mr. M. ... updated

November 3, 2021

E. Ann Misch, MD

Division of Infectious Disease



Department of Medicine

UNIVERSITY OF WISCONSIN

SCHOOL OF MEDICINE AND PUBLIC HEALTH

disclosures and conflicts

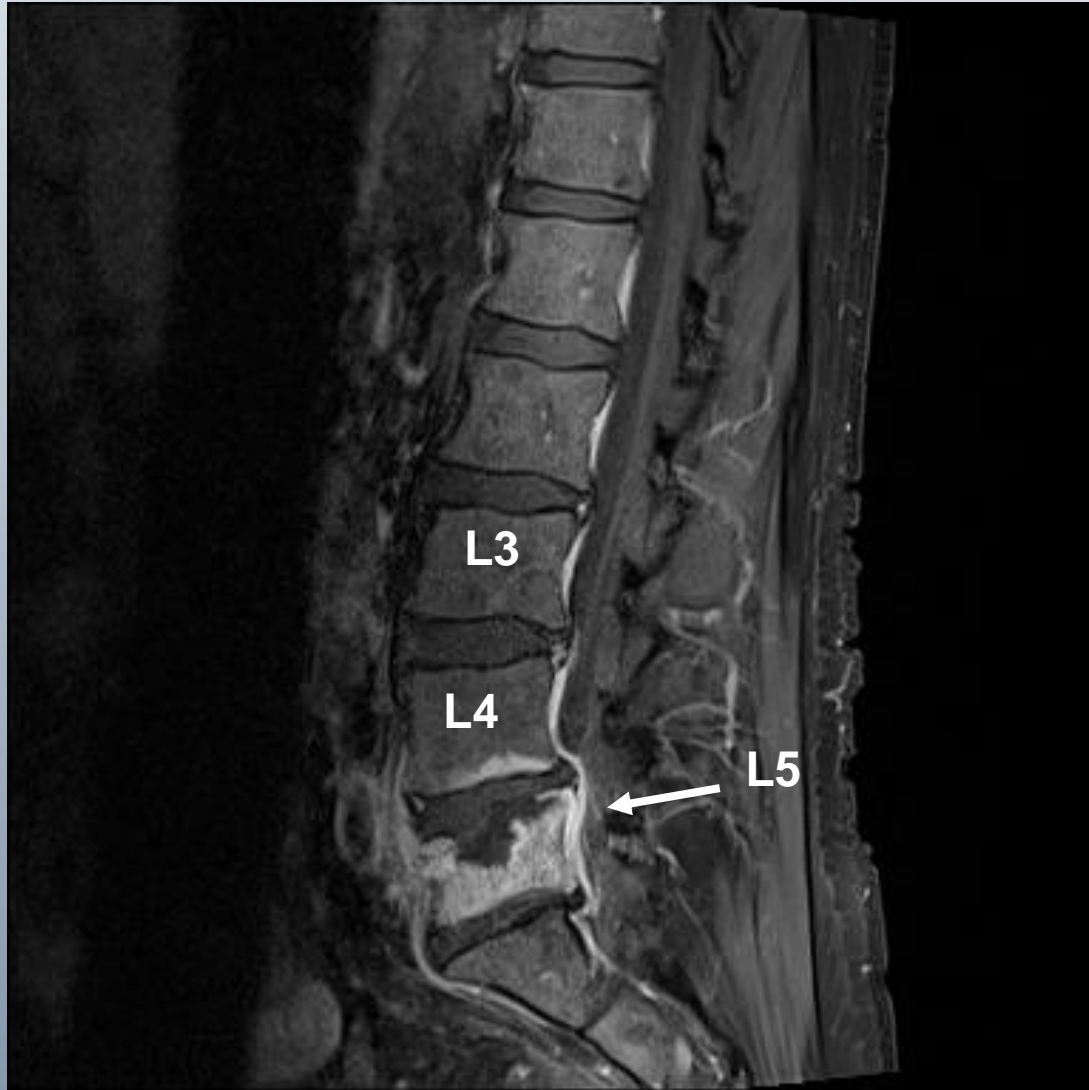- none

HISTORY

- ❑ 60-some year old male
- ❑ history of sarcoidosis
- ❑ long-standing low back pain.
- ❑ 5 months previously, bent over to squeegee his shower and felt the sudden onset of overwhelming pain in his lower back. There was a “popping sensation.”
- ❑ had to recover by sitting in a hard back chair for a period of time. “Thought I had thrown my back out.”
- ❑ Three days later, went to see his chiropractor

HISTORY

- Saw the chiropractor 9 or 10 times over the next three months but continued to have 5/10 to 6/10 pain when flexing spine (for example, bending to pick something up off the floor or squeegeeing his shower, etc.). No or minimal pain when sitting upright or standing.
- 3 1/2 months after symptom onset, MRI of the spine revealed: extensive avid enhancement in the L5 vertebral body, enhancement of L4 inferior endplate and S1 superior endplate, soft tissue enhancement around the spine with small fluid collections



3/14/2018

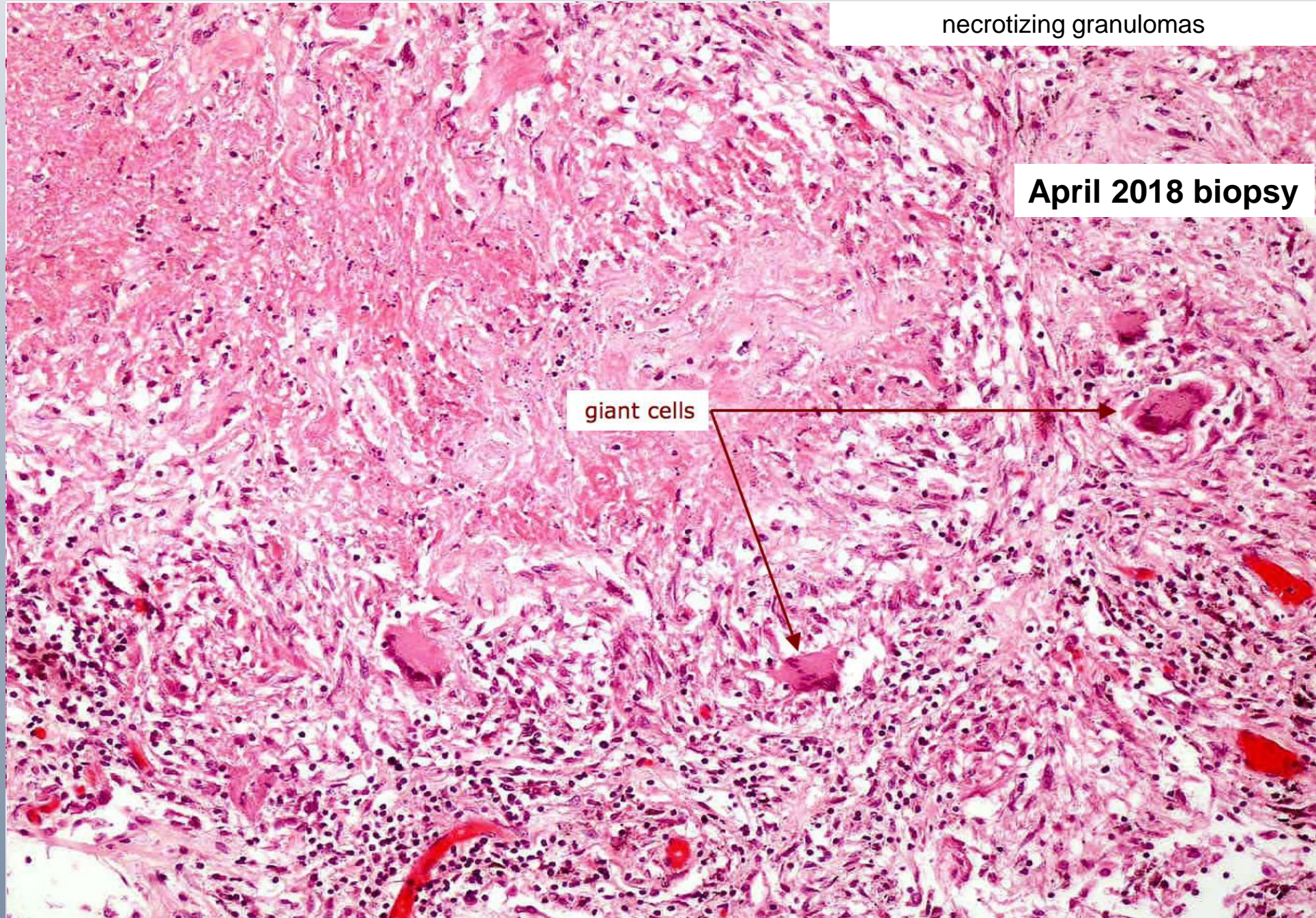
- interventional radiologist performed a CT-guided biopsy
- sampled abscess/ fluid collection and bone
- Pathology: **necrotizing inflammation** of the L5 vertebral body (special stains negative).
- Bacterial, fungal and AFB stains and culture: **negative**
- 16S PCR (for bacterial DNA): **negative**.

April 2018

necrotizing granulomas

April 2018 biopsy

giant cells



HISTORY of illness

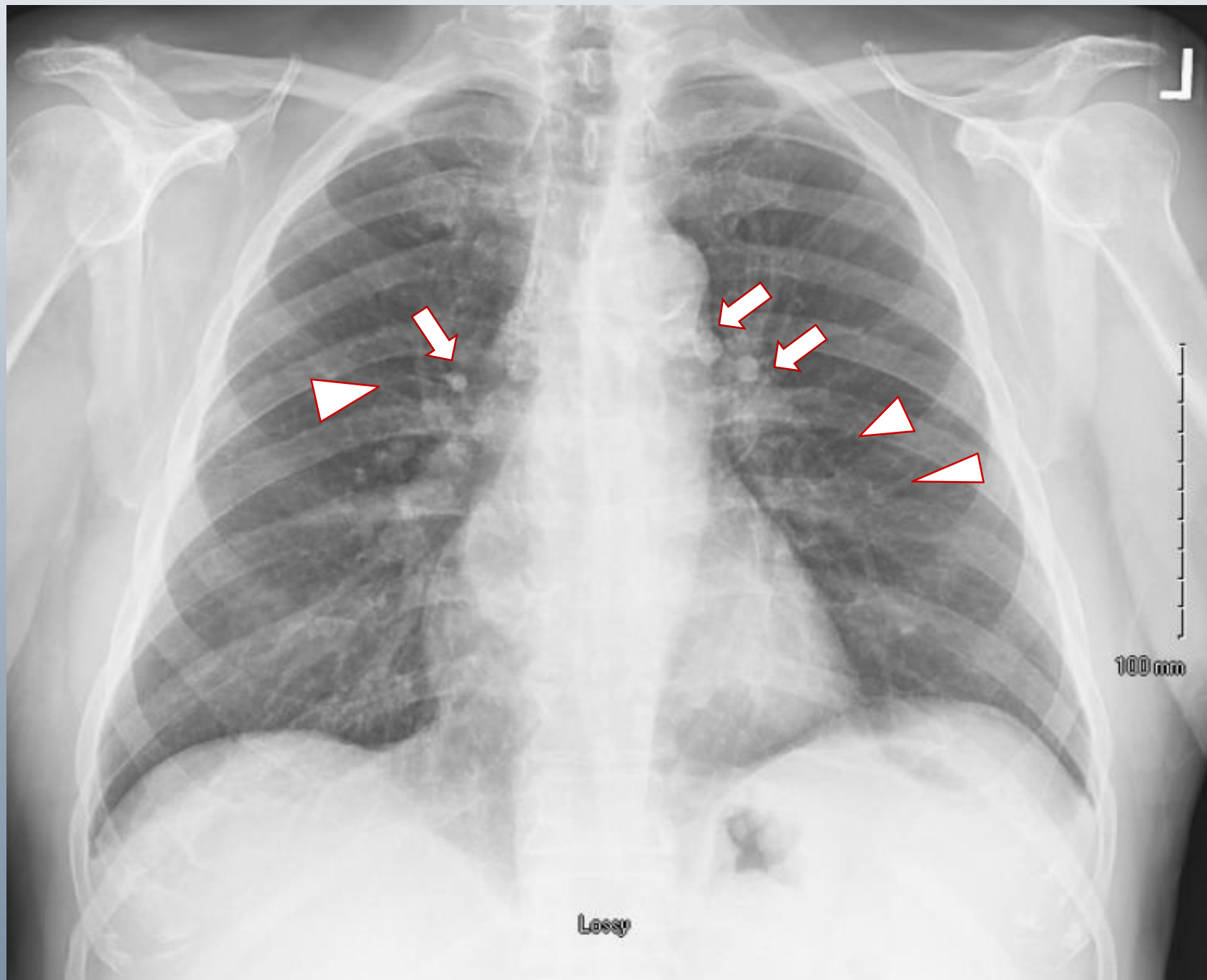
- ❑ **sees Infectious Diseases specialist** mid-April 2018
- ❑ ID review of systems: no fevers, chills, night sweats, weight loss. gets hot at night during the wintertime, which he attributes to winter bedding, and sometimes can sweat a little bit.
- ❑ chronic dry cough for a number of years. Wife notes voice less forceful. coughs and spits up mucus in night often
- ❑ Denies headache, blurry vision, double vision, or vertigo. No imbalance, clumsiness, or falling.
- ❑ No lymph node enlargement.
- ❑ quantiferon gold: negative

Past Medical History

- ❑ Sarcoidosis involving the lung, diagnosed 16 years ago by lung biopsy. Received a prednisone course twice, once around the time of diagnosis and again one to two years later. Not followed by a pulmonologist now and told that his sarcoid is "inactive."
- ❑ gastro-esophageal reflux disease
- ❑ Obstructive sleep apnea.
- ❑ prior pneumonia
- ❑ seasonal allergies

geographic and other exposures

- ❑ born in Illinois. As a boy, had a pet parakeet
- ❑ Travel in the Grand Canyon, Utah, Mexico (Cancun)
- ❑ industrial arts teacher at Junior High school in Illinois, then graphics arts teacher at another high school in Iowa. taught some students from disadvantaged backgrounds
- ❑ spent a lot of time canoeing on Wisconsin River during previous summer
- ❑ no known TB contacts. No family history of TB



- multiple dense small, likely calcified hilar and mediastinal lymph nodes
- mild diffuse interstitial prominence, somewhat perihilar in distribution

Findings outside the lungs

- ❑ Nodular configuration of the liver with splenomegaly.
- ❑ Severe three-vessel coronary artery calcifications and aortic valve calcifications.

- ❑ **second** biopsy
- ❑ sampled abscess/ fluid collection and bone
- ❑ Pathology: **necrotizing inflammation** of the L5 vertebral body (special stains negative).
- ❑ Bacterial, fungal and AFB stains and culture: negative
- ❑ 16S PCR (for bacterial DNA): negative.

June 2018

Next events

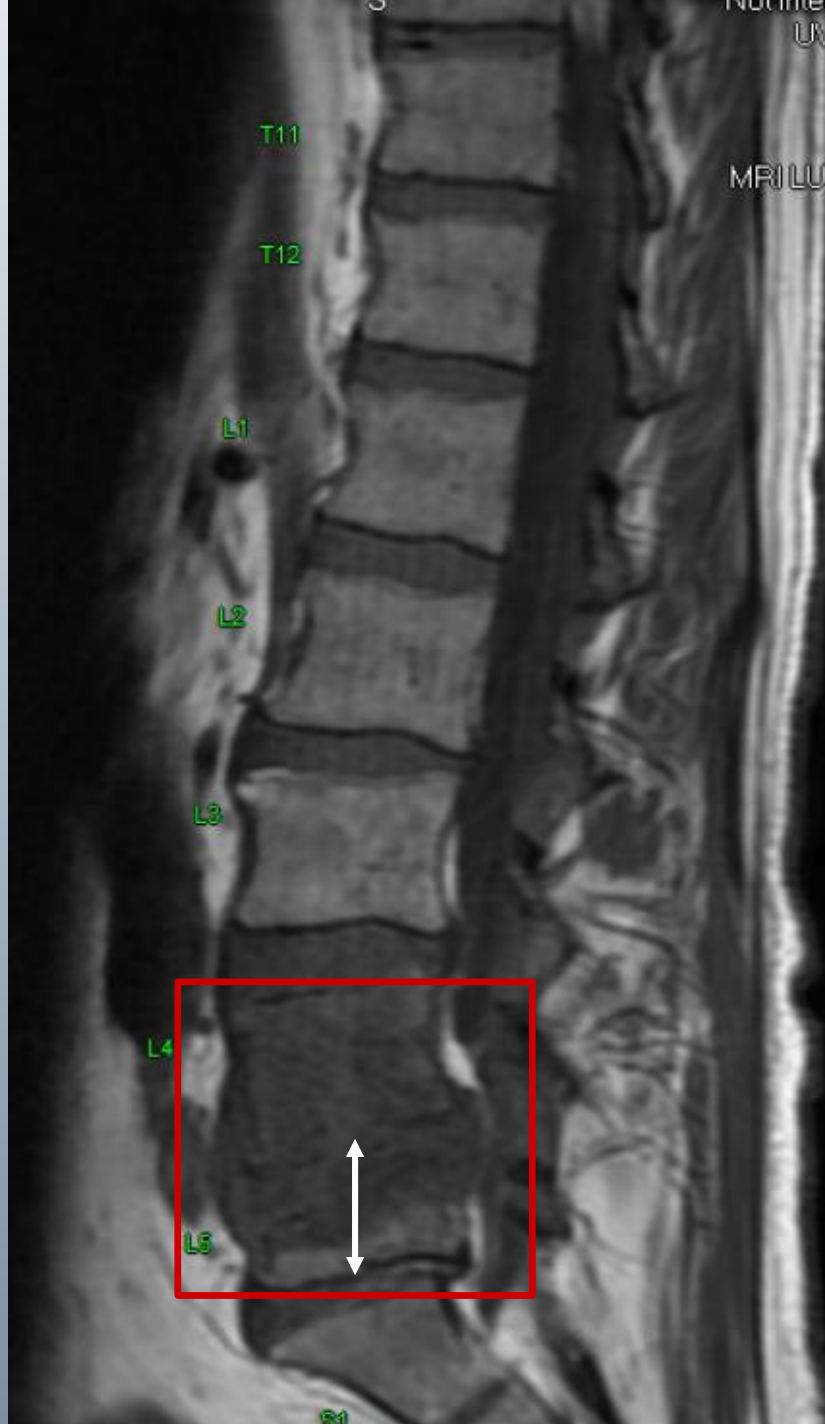
- due to large spleen, esophageal varices, and portal hypertension (all signs of advanced liver disease), sees GI specialist for cirrhosis
- undergoes liver biopsy --
 - non-necrotizing granulomas seen
 - AFB stain/culture, fungal stain/culture, bacterial stain/culture all negative
 - PCRs for bacteria, fungi and mycobacteria all negative

Symptoms

- ❑ in the interim, essentially completely without symptoms.
- ❑ no fevers, chills, night sweats, or unintentional weight loss.
- ❑ may have had a slight decrement in appetite
- ❑ lost 15 lbs of weight intentionally
- ❑ pain only with bending at the waist or back tightness with more prolonged walking

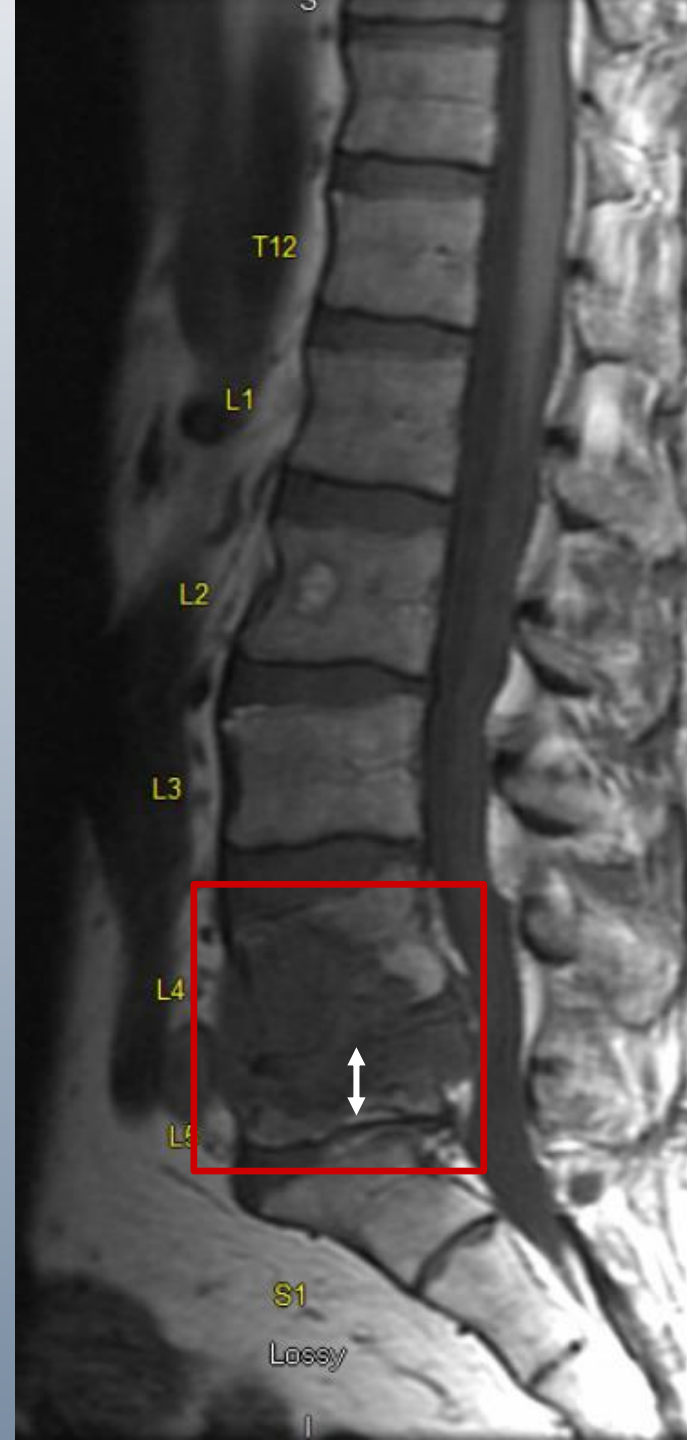
presumptive diagnosis: liver and bone sarcoidosis

- continued to have mild low back pain (3/10). Pain free while sitting. Pain worse with forward bending, lifting, rising from seated position, walking for more than half an hour. Improves when he sits to rest. Difficulty taking out the garbage and mowing the lawn.
- new right buttock and posterior thigh pain at times, and rare numbness to the right great toe.
- started a steroid trial for sarcoidosis with rheumatologist
→pain improved



Nov 2018

T1 FSE



→ pain improved
→ imaging worse

Feb 2019

T1 FSE

further developments ...

- ❑ empiric trial of therapy for sarcoidosis (prednisone 20 mg/d daily and hydroxychloroquine 200 mg/d) October 2018-May 2019, with no improvement
- ❑ loses another 20-25 lbs, this time *un*intentionally
- ❑ admitted May 2019 for surgery to stabilize spine
- ❑ undergoes rod/screw placement, fusion, laminectomy, corpectomy, discectomy of L4-L5
- ❑ AFB smear of operative tissue: **rare AFBs seen**
- ❑ culture: **no growth**
- ❑ PCR: ***M. xenopi***

TABLE 2. CLINICAL DISEASE CAUSED BY NONTUBERCULOUS MYCOBACTERIA (ALPHABETICAL ORDER BY SPECIES)

Common	Page	Comment	Uncommon	Page	Comment
Pulmonary Disease					
<i>M. abscessus</i>	396	Worldwide; may be found concomitant with MAC	<i>M. asiaticum</i> *		Rarely isolated
<i>M. avium</i> complex	386	Worldwide; most common NTM pathogen in U.S.	<i>M. celatum</i> *		Cross-reactivity with TB-DNA probe
<i>M. kansasii</i>	395	U.S., Europe, South Africa, coal-mining regions	<i>M. chelonae</i>	398	
<i>M. malmoense</i>	399	U.K., northern Europe; uncommon in U.S.	<i>M. fortuitum</i>	398	Associated with aspiration
			<i>M. haemophilum</i>	399	Rarely isolated
<i>M. xenopi</i>	402	Europe, Canada; uncommon in U.S.; associated with pseudoinfection	<i>M. scrofulaceum</i>	400	South Africa; uncommon in U.S.
Disseminated Disease					
<i>M. avium</i> complex	386	Worldwide; AIDS; most common NTM pathogen in U.S.	<i>M. abscessus</i>	396	Non-AIDS immunosuppressed
<i>M. chelonae</i>	398	U.S.; non-AIDS immunosuppressed skin lesions	<i>M. celatum</i> *		AIDS
<i>M. haemophilum</i>	399	AIDS; U.S., Australia; non-AIDS immunosuppressed	<i>M. conspicuum</i> *		AIDS, non-AIDS immunosuppressed
<i>M. kansasii</i>	395	AIDS; U.S., South Africa	<i>M. fortuitum</i>	398	Non-AIDS immunosuppressed
			<i>M. genavense</i>	399	AIDS
			<i>M. immunogenum</i>	399	Rare, associated with pseudo-outbreaks
			<i>M. szulgai</i>	401	Rarely isolated
			<i>M. xenopi</i>	402	Europe, Canada, associated with pseudoinfection

epidemiology of *M. xenopi*

- ❑ municipal water supply (incl hot water taps)
- ❑ hospital water supply
- ❑ showerheads
- ❑ soil, sewage sludge
- ❑ slow growing (often > 4 wks)
- ❑ thermophilic: grows well at 45°-55° C
- ❑ resist disinfectants, such as chlorine and formaldehyde

epidemiology of *M. xenopi*

- second most common cause of NTM lung disease in Canada, UK, parts of Europe; *less frequent in U.S*
- lung disease, often with apical cavity
- host often has COPD (emphysema) or other “structural lung disease”
- nosocomial spine infections reported as result of contamination of surgical instruments with tap water
- “pseudo-outbreaks” have been caused by contaminated fiberoptic bronchoscopes
- reported as cause of otitis media

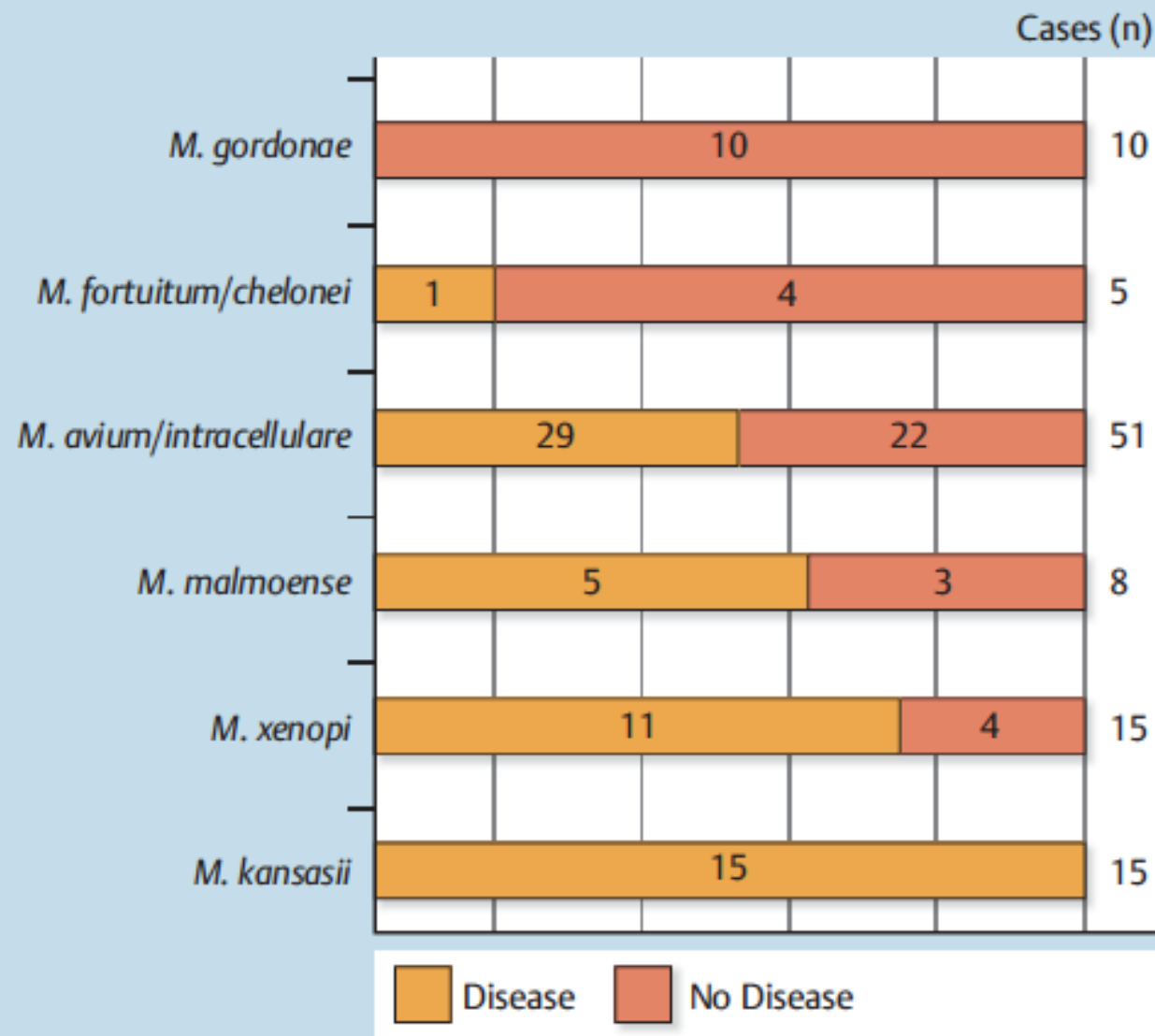


Fig. 1 Morbidity (in pulmonary infections) with the major non-tuberculous mycobacterial species (n=104) [45].

TABLE 1. CHARACTERISTICS OF PATIENTS WITH NONTUBERCULOUS MYCOBACTERIA COLONIZATION, POSSIBLE NONTUBERCULOUS MYCOBACTERIA DISEASE, AND DEFINITE NONTUBERCULOUS MYCOBACTERIA DISEASE

	Colonized Patients (n = 709)	Possible NTM Disease (n = 238)	Definite NTM Disease (n = 335)
NTM species			
<i>Mycobacterium gordonae</i> (n = 485)	392 (55.3)	75 (31.5)	18 (5.3)
<i>Mycobacterium avium</i> complex (n = 425)	137 (19.3)	97 (40.7)	191 (57.0)
<i>Mycobacterium xenopi</i> (n = 52)	14 (1.9)	12 (5.0)	26 (7.8)
<i>Mycobacterium malmoense</i> (n = 46)	12 (1.7)	7 (2.9)	27 (8.1)
Others NRGM (n = 110)	46 (6.5)	25 (10.5)	39 (11.6)
<i>Mycobacterium celatum</i> (n = 25)	11 (1.6)	2 (0.8)	12 (3.6)
<i>Mycobacterium szulgai</i> (n = 12)	0	5 (2.2)	7 (2.1)
Others RGM (n = 164)	108 (15.2)	22 (9.2)	34 (10.1)
<i>Mycobacterium abscessus</i> (n = 58)	28 (3.9)	7 (2.9)	23 (6.9)
<i>Mycobacterium fortuitum</i> (n = 42)	34 (4.8)	4 (1.2)	3 (1.3)

81%

32%

27%

15%

23%

23%

4%

45%

50%

susceptibility testing for *M. xenopi*

“Because too few isolates of each species have been studied, no specific susceptibility method can be recommended at this time ... Until further data are available, testing should be performed as for rifampin-resistant *M. kansasii* (i.e., rifampin and secondary agents should be tested)”

secondary agents:

isoniazid

clarithromycin, azithromycin

ciprofloxacin, moxifloxacin

ethambutol

rifabutin

streptomycin, amikacin

sulfonamides

“the response of this organism to therapy is variable and does not always correlate well with the results of *in vitro* susceptibility.”

treatment recommendations: *M. xenopi*

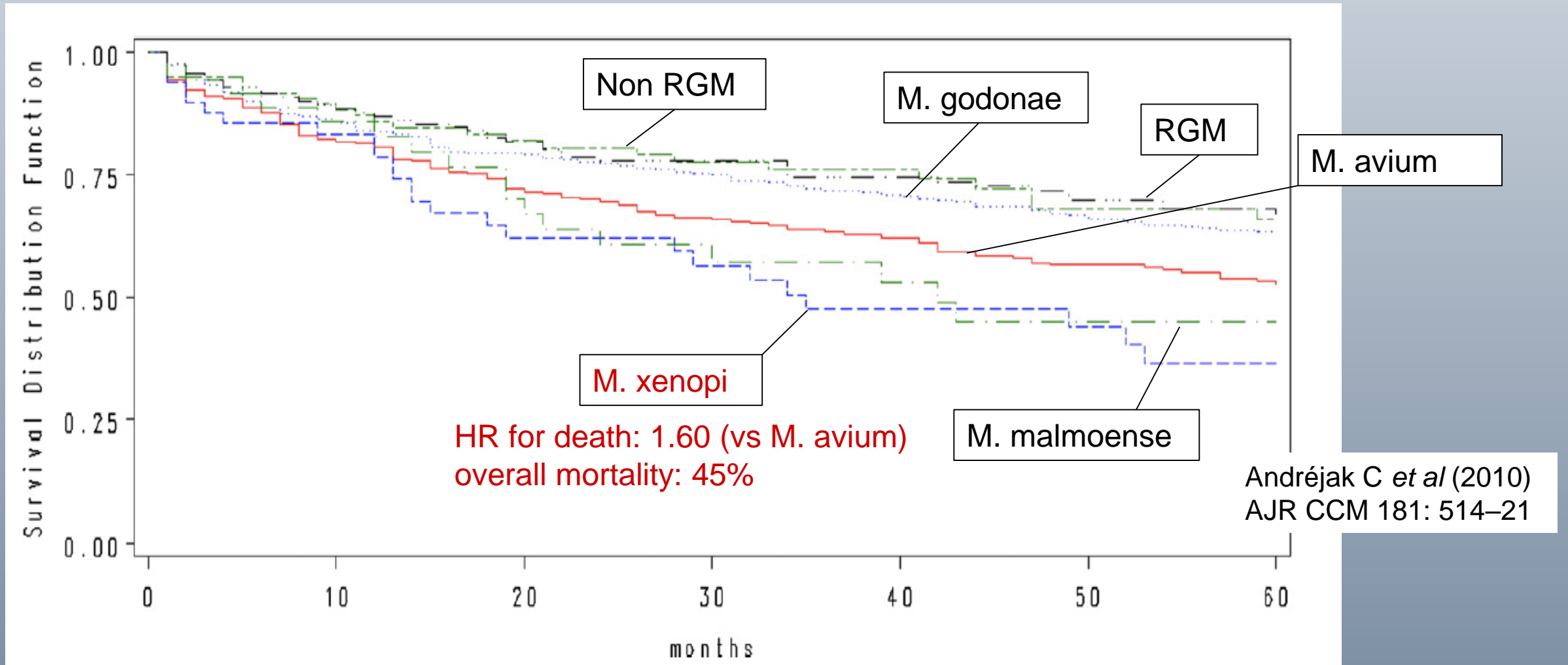
- U.S. guidelines (2007): Isoniazid (INH), rifabutin/rifampin, ethambutol, and clarithromycin +/- initial streptomycin
 - a quinolone may be substituted for one of the anti-tuberculosis drugs
 - duration: continue therapy until patient has maintained negative sputum samples for 12 months
- U.S. Guidelines (2020, pulmonary disease only): multidrug treatment regimen that includes moxifloxacin or macrolide; consider adding IV amikacin in patients with lung cavities or severe bronchiectasis
 - patients should be treated aggressively given high mortality
- German guidelines: same as 2007 U.S. “Isoniazid *in vivo* is considered effective, similar to the situation in *M. kansasii*.”

treatment recommendations: *M. xenopi*

- British Guidelines: **four-drug regimen** (where tolerated) of **rifampicin**, **ethambutol**, **macrolide** (clarithromycin or azithromycin), and a **quinolone** (ciprofloxacin or moxifloxacin) or **isoniazid**.
 - **injectable aminoglycoside** (amikacin or streptomycin) *should be considered* in severe pulmonary disease (ie, AFB smear positive, cavity, severe lung or systemic illness).
 - alternatively, nebulized amikacin may be used
 - continue for a minimum of 12 months after culture conversion.

outcomes: *M. xenopi*

□ most data from studies of pulmonary disease



outcomes: *M. xenopi*

- ❑ mortality: 51% to 69% within 5 years of diagnosis.
- ❑ non-controlled study of 80 patients
- ❑ only 2 Randomized Controlled Trials (RCTs)
 - British Thoracic Society RCT #1 published in 2001
 - ❑ 42 HIV-negative patients treated with RHE or RE only.
 - ❑ 18% failure/relapse with RE vs 5% with RHE (not significant)
 - ❑ RHE associated with increased death
 - British Thoracic Society RCT #2* published in 2008
 - ❑ 32 HIV-neg patients treated with RE+ clarithromycin **or** RE+ ciprofloxacin.
 - ❑ all-cause **mortality higher in those on cipro** (47% vs 29%)
 - ❑ overall cure rates dismal (35%)

R: rifampin (RIF)
H: isoniazid (INH)
E: ethambutol (EMB)

British Thoracic Society RCT #2

Table 5 Comparative outcomes of four regimens in the treatment of lung diseases caused by MAC, *M malmoense* and *M xenopi*

	MAC				<i>M xenopi</i>			
	RE	REH	REClari	RECipro	RE	REH	REClari	RECipro
No of patients	37	38	83	87	22	20	17	17
Deviated from protocol	16%	21%	35%	43%	14%	25%	59%	47%
Deaths (all causes)	32%	39%	48%	30%	55%	85%	29%	47%
Deaths (due to mycobacteria)	0%	8%	2%	3%	0%	15%	0%	6%
Failures of treatment and relapses	41%	16%	13%	23%	18%	5%	24%	6%
Completed treatment as allocated, alive and cured at 5 years	27%	34%	24%	23%	23%	10%	18%	12%

Clari, clarithromycin; Cipro, ciprofloxacin; H, isoniazid; E, ethambutol; MAC, *Mycobacterium* *avium* complex
 Percentages do not always add up to 100% because some patients who died had earlier been

adapted from Jenkins PA (2008) Thorax. 63:627-34.

Back to our patient ...

- ❑ had allergy to macrolides, so initially started on INH, moxifloxacin, ethambutol, rifampin in July 2019
- ❑ underwent desensitization to azithromycin
- ❑ INH stopped 8/1/2019; azithromycin, moxifloxacin, ethambutol, rifampin continued
- ❑ developed rash in mid November 2019; prescribed anti-histamines (cetirizine and famotidine) and a 5 day course of prednisone
- ❑ rash improved, then recurred approx. one month later (Dec 2019). wife described hives. All NTM medications stopped.

Back to our patient ...

- referred to allergist and underwent gradual re-introduction of all meds, each starting at a low dose and increasing each week.
- on resuming rifampin, developed a rash. Rifampin was stopped, and later reintroduced gradually. He was back on all drugs by third week March 2020
- plan to treat for another 12 months, at minimum with
 - Azithromycin 250 mg po daily
 - Ethambutol 1,200 mg po daily
 - moxifloxacin 400 mg po daily
 - Rifampin 600 mg po daily

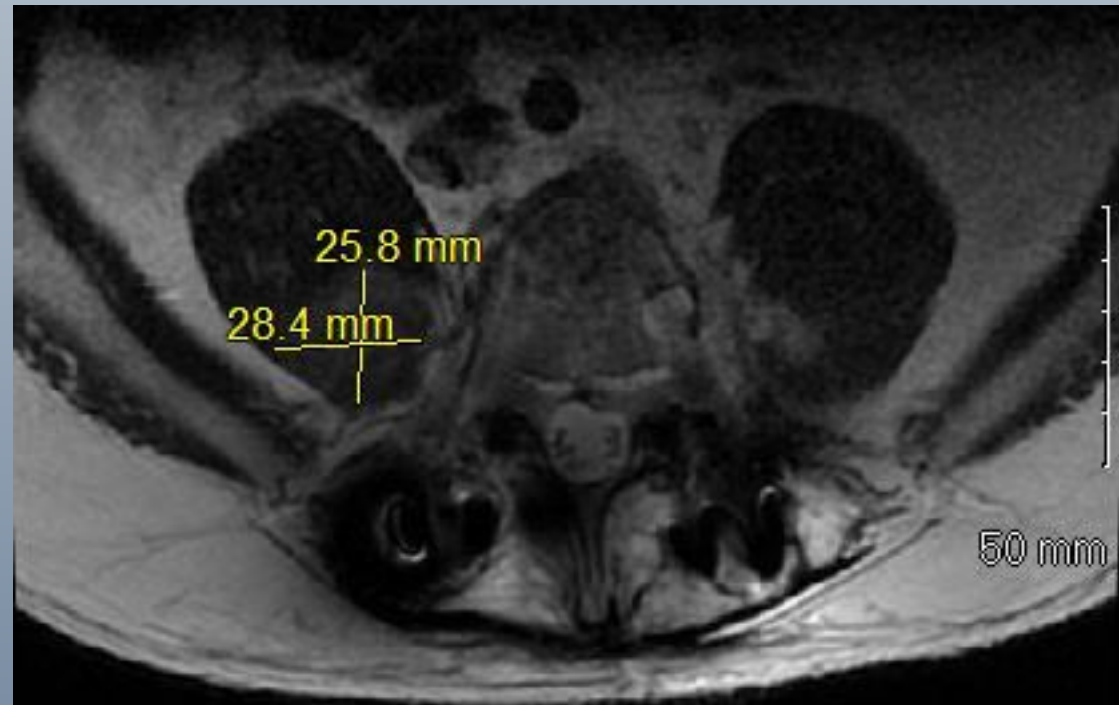
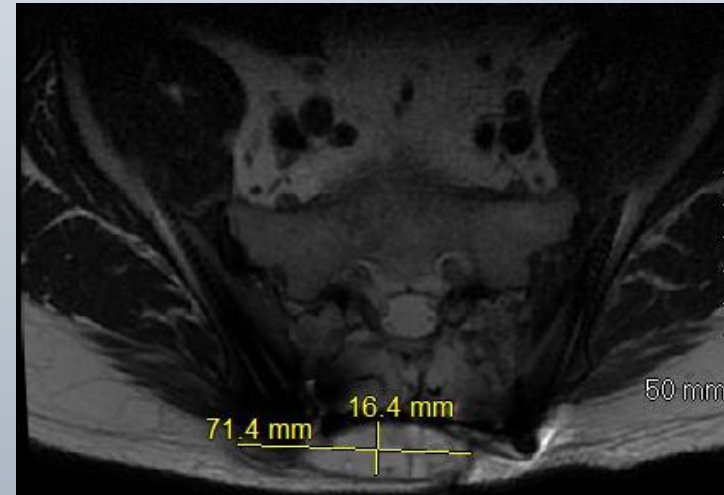
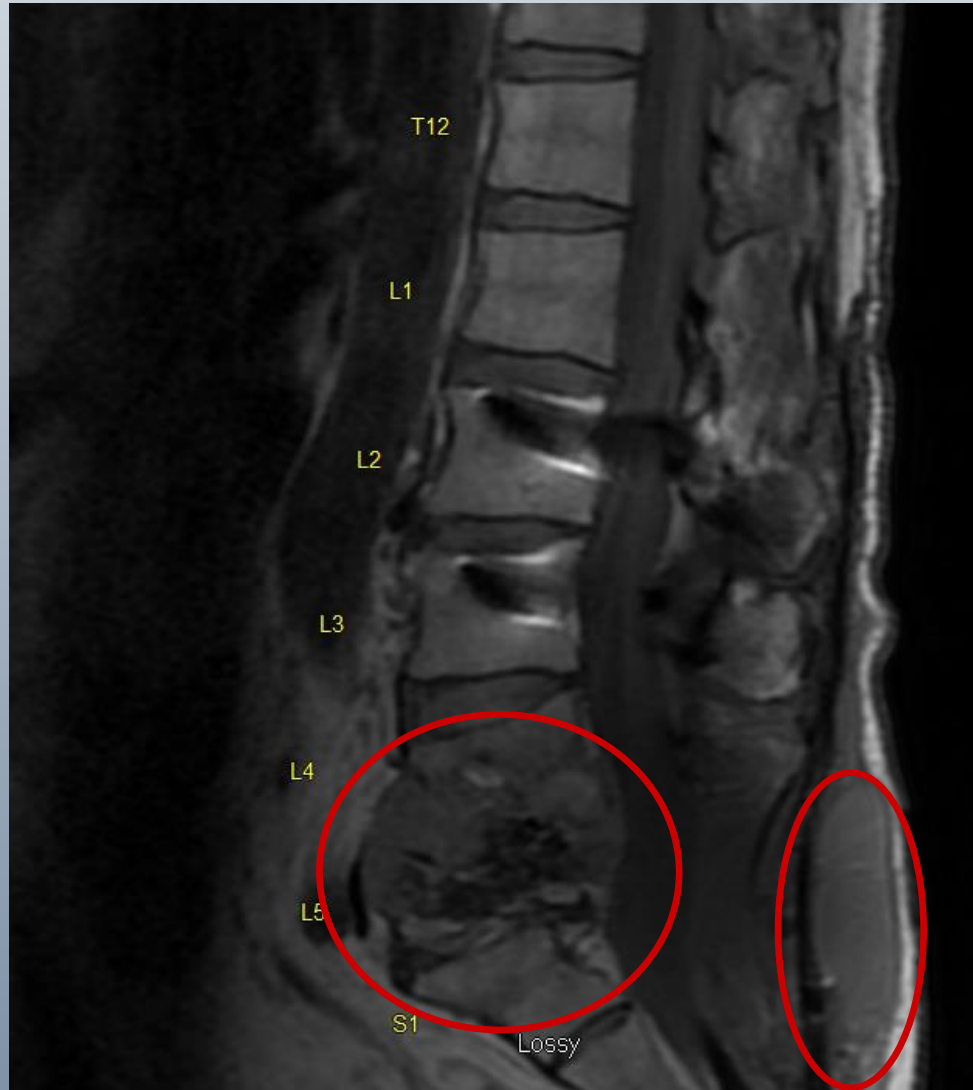subsequent events

- referred to hematology for progressive pancytopenia. Thrombocytopenia, leukopenia attributed to enlarged spleen/cirrhosis. Anemia felt due to poor oral intake, iron deficiency. Oral iron and folate replacement started.
- seen Oct 2020, and doing well without any rash
- Jan 2021 reports new symptoms in clinic:
 - a “lipoma” had appeared over his old spine surgery scar approx. one month ago
 - new rash presenting as scattered skin “blisters” that “pop open”
 - Denies fever, chills, night sweats, **diarrhea**

Back to our patient ...

- MRI of the spine shows:
 - complex T2 enhancing fluid collection with internal septations and debris, measuring roughly 1.6 x 7.1 x 7.6 cm, in the subcutaneous tissues overlaying the L4-S2 levels with spinal hardware hardware
 - phlegmon of the right psoas muscle
- relapse of M. xenopi spine infection strongly suspected

repeat spine MRI Jan 2021



relapse ... and other events

- undergoes IR guided aspiration on 1/14/2021:
 - AFB smear positive
 - AFB culture negative
 - PCRs for *M. xenopi* and other mycobacteria neg
- undergoes **2nd** aspiration in OR, 3/18/2021:
 - AFB smear positive
 - AFB culture negative
 - PCRs for *M. xenopi* positive

relapse ... and other events

- presents to Emergency department with complaint of diarrhea on 3/28/2021
 - diarrhea began on 3/25 and he has had 10 to 15 episodes per day. The diarrhea was initially watery. He started to notice blood in his stool yesterday.
 - admitted with diagnosis of gastrointestinal (GI) bleed. receives 1 unit of blood; undergoes EGD, which shows esophageal varices which are banded
 - treated with 5 days of antibiotics; 72 hours of octreotide, IV proton pump inhibitor, and discharged on pantoprazole and propranolol to prevent another GI bleed

dru

□ ir

NTM drug levels on original (4/12/2021) and increased (7/6/2021) dose NTM regimen

Drug and dose	expected range (mcg/ml)	2 hr post dose level*	6 hr post dose level*
1st measurement: 4/12/2021			
azithromycin 250 mg	0.2-0.7 (2-3 hrs after dose)	0.06	Nat Jew lost sample
ethambutol 1200 mg	2-6 (2-3 hrs after dose)^	1.60 (too low)	Nat Jew lost sample
rifampin 600 mg	8-24 (2 hrs after dose)	4.12 (too low)	Nat Jew lost sample
moxifloxacin 400 mg	3-5 mcg/ml (2 hrs after dose)	2.51 (too low)	Nat Jew lost sample
2nd measurement: 7/6/2021			
azithromycin 500 mg	0.2-0.7 (2-3 hrs after dose)	0.08 (too low)	0.10 (too low)
ethambutol 1600 mg	2-6 (2-3 hrs after dose)^	2.63 (OK)	1.38
rifampin 1200 mg	8-24 (2 hrs after dose)	2.82 (too low)	21.53 (good)
moxifloxacin 600 mg	3-5 mcg/ml (2 hrs after dose)	3.82 (OK)	3.74 (OK)

drug dosing/ levels and immunodeficiency workup

□ drug dosing increased

- Azithromycin eventually increased 1,000 mg/day
- Ethambutol increased to 1,600 mg po daily
- moxifloxacin increased to 600 mg po daily
- Rifampin 600 mg po daily

□ Immunodeficiency workup:

- anti-interferon γ antibodies (neg)
- Mendelian Susceptibility to Mycobacterial Disease (neg)
- HIV testing neg
- flow cytometry: low CD8, CD4, and NK cell numbers, likely 2nd to cirrhosis. CD4 count “normal for age”

surgical debridement

- underwent irrigation and debridement (washout, without removal of spinal hardware), in May 2021
 - AFB smear positive
 - AFB culture negative
 - PCRs for *M. xenopi* and all other mycobacteria negative

slow decline

- ❑ skin blisters diagnosed as bullous pemphigoid
- ❑ admitted in August 2021 with a 2nd GI bleed. More varices banded and 5L of ascites removed from abdomen.
- ❑ admitted early Sept 2021 with acute kidney injury and abdominal pain in the context of diarrhea (15 BMs/day). No infectious etiology found, even after colonoscopy with biopsy.
- ❑ during 2-wk hospitalization, **NTM therapy held**. abx considered as cause of kidney failure, but ultimately attributed to dehydration from diarrhea.

slow decline

- ❑ discharged in mid-Sept, off abx, with ID follow up scheduled in mid-Oct
- ❑ elected hospice and did not restart NTM medications
- ❑ expired 10/20/2021.

END

